

Comparative Trial Between Sodium Tetradecyl Sulfate and Glycerin in the Treatment of Telangiectatic Leg Veins

BRIAN C. LEACH, MD, AND MITCHEL P. GOLDMAN, MD

Dermatology/Cosmetic Laser Associates of La Jolla, Inc., La Jolla, California

BACKGROUND. Thirteen patients were treated with either sodium tetradecyl sulfate (STS) or glycerin to compare the efficacy and adverse sequelae of each agent.

OBJECTIVE. To determine the relative safety and efficacy of two sclerosant solutions.

METHODS. Each patient's leg veins that were from 0.2 to 0.4 mm in diameter and that did not have incompetence from the saphenofemoral junction and whose feeding reticular veins had been already treated in a prior sclerotherapy session were randomly treated with either 0.25% STS or 72% glycerin solution. Patients were evaluated from 2 to 6 months

postsclerotherapy for overall clinical improvement and incidence of adverse sequelae.

RESULTS. Glycerin was comparable to STS in discomfort of injection but demonstrated a significant decrease in bruising, swelling, and postprocedural hyperpigmentation. Glycerin also demonstrated a better, more rapid clearance of treated telangiectasias.

CONCLUSIONS. Seventy-two percent glycerin is a safe and effective sclerosant with fewer side effects and more rapid clearance of telangiectatic leg veins than STS.

B. C. LEACH, MD, AND M. P. GOLDMAN, MD HAVE INDICATED NO SIGNIFICANT INTEREST WITH COMMERCIAL SUPPORTERS.

SCLEROSING SOLUTIONS can be placed into three broad categories based on their mechanisms for producing endothelial injury: detergent, osmotic, or chemical irritant solutions. There are an infinite number of potential solutions that when injected intravascularly can cause endothelial and vascular wall necrosis. In addition, an infinite variety of various combinations or mixtures of solutions can be used to produce endosclerosis. Sclerosing solutions should ideally be painless to inject, free of adverse effects, and specific for damaged (varicose) veins.¹ This article evaluates the relative safety and efficacy of a detergent sclerosing solution, sodium tetradecyl sulfate (STS), and a chemical irritant sclerosing solution, glycerin.

because when diluted with blood, the molecules attach to the surface of red blood cells, causing hemolysis.

STS is a widely used sclerosant for the treatment of telangiectatic veins and one of only three sclerosing agents (sodium morrhuate, ethanolamine oleate, and STS) approved for use in the United States by the Food and Drug Administration. Concentrations of 0.1% to 0.3% are commonly used for the treatment of telangiectatic veins that are 0.2 to 1.0 mm in diameter, 0.5% to 1% for treatment of uncomplicated varicose veins that are 2 to 4 mm in diameter, and 1.5% to 3% for the treatment of larger varicose veins.³

STS

STS is a synthetic, surface-active substance that is composed of sodium 1-isobutyl-4-ethyloctyl sulfate plus benzoyl alcohol 2% (as an anesthetic agent) and that is phosphate buffered to pH 7.6. It is a long-chain fatty acid salt of an alkali metal with the properties of soap. The solution is clear and nonviscous and has a low surface tension. It is readily miscible with blood.² It primarily acts on the endothelium of the vein

Glycerin

Glycerin (glycerol, 1,2,3-propanetriol, glycerine)⁴ is a potent osmotic dehydrating agent that is primarily used clinically in the treatment of elevated intracranial pressure.⁵ The sclerosing quality of glycerin was first studied in 1925 by Jausion et al.,⁶ who found that it induced a mild, rapid, and complete endosclerosis. Isosmotic glycerol (2.6% m/v) produces 100% hemolysis in 45 minutes.^{7,8}

Chromated glycerin 72% (CG), also known as Chromex (Omega Laboratories, Montreal, Canada) and Sklermo (Alet Laboratorios S.A., Buenos Aires, Argentina), is a sclerosing solution that is popular in Europe, whereas clinical experience in the United States remains limited. The chromium alum

Address correspondence and reprint requests to: Mitchel P. Goldman, MD, Dermatology/Cosmetic Laser Associates of La Jolla, Inc., 7630 Fay Avenue, La Jolla, CA 92037, or e-mail: mgoldman@spa-md.com.

component of CG is a potent coagulating factor that increases the sclerosing power of glycerin. It also prevents the mild hematuria induced through the use of glycerin alone.^{6,9,10} The maximum recommended amount per injection session is 10 mL of pure solution. Concentrations of 25% to 100% have been used.¹¹ Its clinical efficacy has been shown to be dose dependent. CG, although not approved by the Food and Drug Administration, is the most widely used sclerosing agent for leg telangiectasias in the world; 500,000 vials were sold in 1986.¹²

Mihael Georgiev (personal communication, 1994) has produced a 70% sterile glycerin solution for injection and has seen a sclerosing effect with this agent that is identical to CG. Hobbs has confirmed this effect as well with 72% glycerin solution mixed with lidocaine 0.5% (personal communication, 2000). Because glycerin is available on formulary for use in cerebral edema and acute glaucoma, its availability makes it a promising alternative to more caustic sclerosing agents.¹

Methods

A total of 13 patients with telangiectatic leg veins without incompetence at the saphenofemoral, or saphenopopliteal junctions were treated with two sclerosant solutions. All veins treated were 0.2 to 0.4 mm in diameter without evidence of feeding reticular veins. In each patient, all telangiectatic superficial veins of one leg were treated with STS 0.25% solution, and the veins of the other leg were treated with sterile glycerin 72% solution mixed 2:1 with 1% lidocaine with epinephrine 1:100,000. Treatment was performed in a standard technique as previously described.¹

A statistical analysis was not performed because only 13 patients were treated. Because the superficial venous system is interconnected, individual veins were not analyzed, but the entire telangiectatic superficial system was treated in one session. The patient subjectively assessed the pain at the time of injection. The degree of pain was not assessed. The patient was merely asked if the procedure/injection was painful. The treating physician objectively assessed at clinical follow-up visits the bruising, swelling, hyperpigmentation, and vessel clearance.

Results

A total of 13 patients were evaluated, with bilateral treatment of leg telangiectasias. All subjects were female, with an average age of 57 years (range of 41 to 70). The volume of sclerosant ranged from 2 to 10 mL

(mean, 6.9 mL). Follow-up periods ranged from 2 to 6 months. The findings are demonstrated in Table 1.

The most frequent complication observed was hyperpigmentation, in leg veins treated with STS, occurring in 92% of the patients. Glycerin was comparable to STS in discomfort of injection, although it demonstrated a significant decrease in bruising, swelling, and postprocedural hyperpigmentation. Glycerin also demonstrated better, more rapid clearance of treated superficial vessels.

Discussion

Glycerin (Figure 1) is a naturally occurring trivalent alcohol that constitutes the structural core of the triglyceride molecule in humans. Glycerin is incorporated into intermediate metabolism via two major pathways,⁵ being rapidly absorbed by the intestine and transformed into carbon dioxide or glycogen, or is directly used for the synthesis of fatty acids.⁷

Approximately 80% of glycerin metabolism occurs in the liver, whereas 10% to 20% occurs in the kidney; this distribution corresponds to the primary locations of glycerol kinase.¹³⁻¹⁵ The elimination half-life of glycerin in humans is approximately 30 to 45 minutes.^{13,16} When a serum concentration of 0.15 mg/mL is exceeded, glycerin appears in the urine and causes an osmotic diuresis that is roughly equivalent to the volume administered.^{17,18}

Table 1. Summary of Adverse Events and Efficacy by Treatment Group

Adverse Event/Efficacy	Glycerin (N = 13)	STS (N = 13)
Pain	(3) 23%	(2) 15%
Bruising	(1) 8%	(7) 54%
Swelling	(0) 0%	(3) 23%
Hyperpigmentation	(1) 8%	(12) 92%
Vessel clearance	(7) 54%	(1) 8%

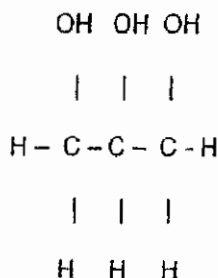


Figure 1. Chemical formula of glycerin.

Intravenous glycerol has primarily been used clinically for its potent osmotic dehydrating effect. Glycerin in doses of 0.25 to 2.0 g/kg dramatically decreases intracranial pressure for the treatment of stroke, pseudotumor cerebri, encephalitis, and space occupying lesions and is effective in rapidly lowering intraocular pressure in glaucoma.^{5,19,20} Notable adverse reactions of glycerin in humans include intravascular hemolysis, hemoglobinuria, renal damage, hyperglycemia, and hyperosmolality. Glycerin is incorporated into the Embden-Meyerhof pathway, resulting in an increase in serum glucose concentration. Because of this metabolism and the potential to create a profound hyperosmotic state with continued use, glycerin must be used with caution in diabetic patients.⁵

Virno et al.²⁰ recorded no adverse reactions using a 30% intravenous glycerin solution in the treatment of glaucoma at rates of 0.6 g/kg over a single 15- to 20-minute dose, and in the extensive review by Frank et al.,⁵ no significant toxicity was noted at glycerin doses of 2.0 g/kg of intravenous infusion over 2 hours. In our study, the 72% glycerin solution, when diluted with lidocaine, yields a solution of 0.48 g glycerin/mL and a total delivered dose of 4.8 g of glycerin at the recommended volume (10 mL) of sclerosant. No adverse effects were noted in our study, and this dose is a fraction of the levels cited with toxicity.⁵

As with CG, the major disadvantages of glycerin as a sclerosant include its high viscosity and local pain at injection. Both of these drawbacks are partially overcome by dilution with lidocaine in the sclerosant solution. The addition of the lidocaine acts to minimize postsclerosis pain and cramping and to decrease solution viscosity, and the epinephrine component of the dilutant may facilitate vessel constriction after injection.²¹ In our study results, injection pain of glycerin diluted with lidocaine yielded results that are comparable to STS injection.

The major advantages of glycerin as a sclerosant include rare incidence of hyperpigmentation and necrosis,²¹ and this was also reinforced in our study results. Glycerin injection resulted in a marked decrease in hyperpigmentation compared with STS, with no events of necrosis. Physicians who use STS in their clinical practice may seem surprised by the high incidence of pigmentation after treatment. This may be secondary to a concentration of 0.25% STS being used that may be excessive or secondary to careful observation. Pigmentation in every patient resolved between 6 and 12 months after injection. Glycerin also showed significant decreases in swelling and bruising after injection and a more rapid vessel clearance over STS. The more rapid and significant

clearing rate of glycerin in this study suggests an increased efficacy of this solution in treating telangiectasia.

Our study results demonstrate glycerin as a safe and effective sclerosant with fewer side effects and more rapid clearance of telangiectatic leg veins than STS. Given the availability of glycerin on formulary, it has great potential for increased use as a well-tolerated, efficacious sclerosing agent with a low incidence of adverse effects.

References

- Goldman MP, Bergan JJ. Sclerotherapy Treatment of Varicose and Telangiectatic Leg Veins, 3rd ed. St. Louis: Mosby, 2001.
- Reiner L. The activity of anionic surface active compounds in producing vascular obliteration. *Proc Soc Exp Biol Med* 1946;62:49.
- Goldman MP. Treatment of varicose and telangiectatic leg veins: double-blind prospective comparative trial between aethoxyskerol and sotradecol. *Dermatol Surg* 2002;28:52-5.
- National Institute for Occupational Safety and Health. Glycerol: The Registry of Toxic Effects of Chemical Substances. July 2000, RTECS♯ MA8050000.
- Frank MSB, Nahata MC, Hilty MD. Glycerol: a review of its pharmacology, pharmacokinetics, adverse reactions and clinical use. *Pharmacotherapy* 1981;1:147-60.
- Jausion H, Carrot E, Ervais A. Une methode simple de phleboscлерose: la cure des varices par les injections de glycerine diluee. *Bull Soc Fran Dermatol Syph* 1931;38:171.
- Martindale. The Extra Pharmacopoeia, 28th ed. London: The Pharmaceutical Press, 1982:706-7.
- Hannarlund ER, Pedersen-Bjergaard L. Hemolysis of erythrocytes in various iso-osmotic solutions. *J Pharm Sci* 1961;50:24.
- Jausion H. Glycerine chromee et sclerose des ectasies veineuses. *La Presse Med* 1933;53:1061.
- Jausion H, Medioni G, Pecker A, Gozlan W. La sclerose des varices et des hemorrhoids par le glycerine chromee. *Bull Memoires Soc Med Hospitaux Paris* 1932;587.
- Ouvry PA. Telangiectasia and sclerotherapy. *J Dermatol Surg Oncol* 1989;15:177-81.
- Sclerono Product Information. France: Laboratories E. Bouteille, 1987.
- Tourtellotte WW, Reinglass JL, Newkirk TA. Cerebral dehydrating action of glycerol. I. Historical aspects with emphasis on the toxicity and intravenous administration. *Clin Pharmacol Ther* 1972;13:159-71.
- Borchgrevink CF, Havel JR. Transport of glycerol in human blood. *Proc Soc Exp Biol Med* 1969;113:946-8.
- Holst EJ. Glycerol oxidation in the animal organism. *Acta Physiologica Scand* 1944;7:69-79.
- Nahata MC, Kerzner B, McClung HJ, et al. Variations in glycerol kinetics in Reye's syndrome. *Clin Pharmacol Ther* 1981;29:782-7.
- Zalversmit DB, McCandless EL. Fate of intravenously administered glycerol. *Proc Soc Exp Biol Med* 1957;95:755-7.
- Kruhoffer P, Nissen OI. Handling of glycerol in kidney. *Acta Physiologica Scand* 1963;59:284-94.
- Sears ES. Nonketotic hyperosmolar hyperglycemia during glycerol therapy for cerebral edema. *Neurology* 1976;26:89-94.
- Virno M, Bucci MG, Pecori-Giraldi J, et al. Intravenous glycerol-vitamin C (sodium salt), as osmotic agents to reduce intraocular pressure. *Am J Ophthalmol* 1966;62:824-33.
- Martin DE, Goldman MP. A comparison of sclerosing agents: clinical and histologic effects of intravascular sodium tetradeceyl sulfate and chromated glycerin in the dorsal rabbit ear vein. *J Dermatol Surg Oncol* 1990;16:18-22.

Commentary

The quest for the perfect sclerosant continues. We are always looking for improved sclerosing agents to treat cosmetic telangiectatic and symptomatic varicose veins. The recent advent of foam sclerosing agents has been a major advance in this field.

Phlebologists understand that because of pain and an increased adverse side-effect profile hypertonic saline is not the optimal sclerosant for today.

STS (Sotradecol) is the most commonly used sclerosing agent in the United States at this time. It has great concentration versatility (0.1% to 3.0%), minimal allergenicity, and a good safety profile. However, we are always working for improved results and a diminished concentration profile. Many phlebologists around the world feel that Polidocanol (Aethoxysklerol) fits the bill. However, this agent has not achieved Food and Drug Administration approval at this time, and previously published studies have shown comparative efficacy and side-effect profile to Sotradecol in equivalent concentrations.

This brings us the present publication by Leach et al. CG (Scleremo) has been used by our European colleagues for many years as an important minor sclerosing agent for treatment of small telangiectasia that are less than 1 mm in diameter. Allergenicity has been an issue surrounding this sclerosing agent in the past. The authors in this study combine this agent with lidocaine and epinephrine and show superior results and decreased pigment dyschromia when comparing this agent to Sotradecol in the treatment of small spider veins. The marked increased efficacy and significant lower side-effect profile with no evidence of hypersensitivity reaction are worthy findings that require further substantiation by future double-blinded controlled studies. If these results are verified by other investigators, we may have a better sclerosing agent for treatment of small cosmetic telangiectases.

NEIL SADICK, MD
New York, NY